

Data supplement

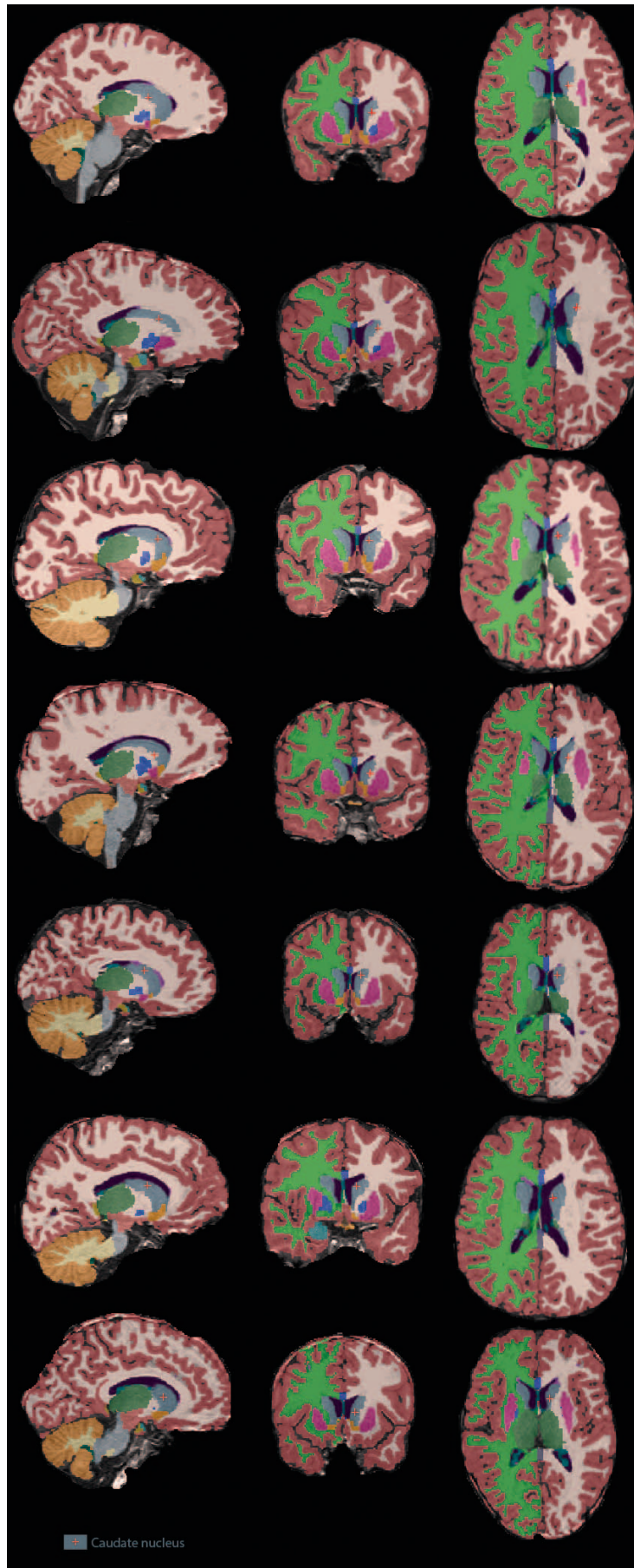


Fig. DS1 Sagittal, coronal and transaxial slices of the segmentation of the left and right caudate nucleus (in grey-blue), and the left and right putamen (in purple).

+, caudate nucleus.