

## TBI (N=39) < Control (N=17)

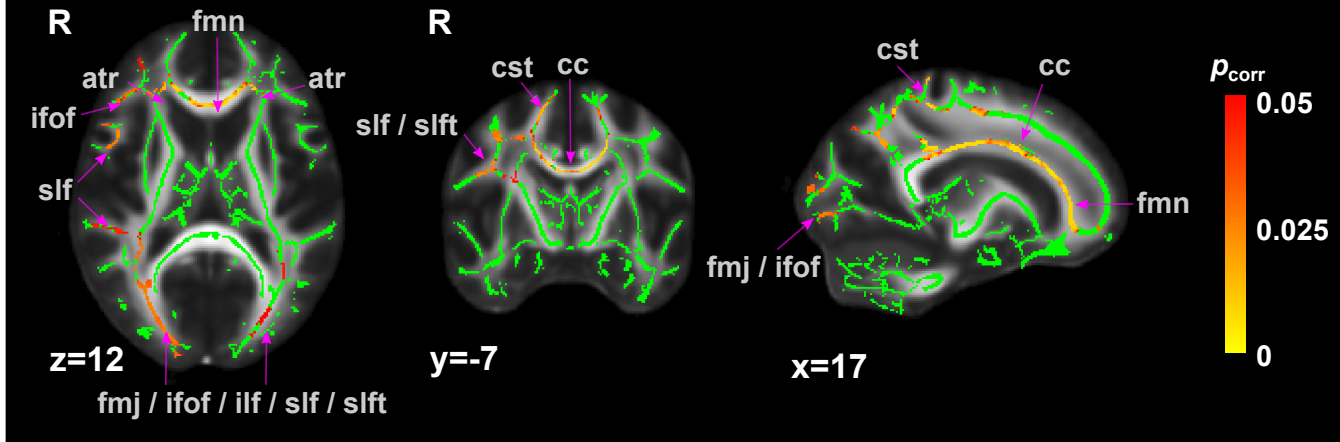


Fig. S8. Group comparisons of fractional anisotropy using tract-based spatial statistics ( $p_{\text{corr}} < 0.05$  with threshold-free cluster enhancement). The green lines are the skeletonized tracts drawn on the mean FA images obtained by averaging all FA maps registered to the FA template in the MNI 152 space. atr, anterior thalamic radiation; cc: corpus callosum (body); cst, corticospinal tract; fmj, forceps major; fmn, forceps minor; ifof, inferior fronto-occipital fasciculus; ilf, inferior longitudinal fasciculus; slf, superior longitudinal fasciculus; slft, superior longitudinal fasciculus (temporal).